

## Cardiac Imaging

# Treatment of a Large Rupture of the External Iliac Artery by Implantation of a Coated Metal Stent

MICHALIS I. HAMILOS<sup>1</sup>, GEORGE E. KOCHIADAKIS<sup>1</sup>, ADAM A. HATZIDAKIS<sup>2</sup>, PANOS E. VARDAS<sup>1</sup>

<sup>1</sup>Cardiology Department, <sup>2</sup>Radiology Laboratory, Heraklion University Hospital, Crete, Greece

Key words:  
Iliac artery, stent.

Manuscript received:  
April 5, 2005;  
Accepted:  
May 12, 2005.

Address:  
Michalis I. Hamilos

Cardiology Department  
Heraklion University  
Hospital,  
P.O. Box 1352 Stavrakia,  
711 00 Heraklion  
Crete, Greece  
e-mail:  
[cardio@med.uoc.gr](mailto:cardio@med.uoc.gr)

A man aged 70 years was admitted to our department for programmed coronary angiography because of angina on effort and a previous positive exercise test. His history included hypertension, hyperlipidaemia and mild chronic renal failure.

During access to the left femoral artery the patient experienced sudden pain in the region, while at the same time there was a large extravasation of contrast medium at the level of the external iliac artery, at a point where the vessel showed stenosis and dissection (Figure 1). The vessel rupture was treated immediately, by the introduction of a hydrophilic guide wire (Terumo, 0.035") and placement of a drug-eluting stent (Jostent Peripheral, 4-9 mm/48 mm), followed by dilation of a Fox PTA 7/40 mm balloon (Figure 2). The final angiographic outcome was excellent, with complete restoration of flow in the vessel without signs of contrast medium extravasation (Figure 3).

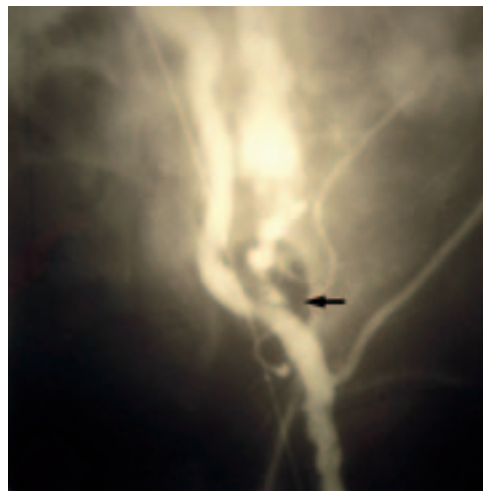The coronary angiographic examination was completed and revealed three-vessel disease. Throughout the examination the patient remained haemodynamically stable, with a moderate drop in haematocrit (from 42% to 35%) which did not necessitate transfusion. An echocardiographic examination a few hours later showed a moderately sized perivascular haematoma, with no signs of continuing haemorrhage or pseudoaneu-

rysm. Computed tomography depicted the contrast extravasation within the haematoma with no sign of active haemorrhage. The patient remained in hospital for 24 hours and was discharged in good general condition with a recommendation for surgical treatment of his coronary artery disease.


Iatrogenic rupture of the iliac artery is a relatively rare complication (around 0.5% of iliac angioplasties), which may occur either acutely or subacutely with the formation of a pseudoaneurysm.<sup>1</sup> It is usually treated surgically. Acute rupture is particularly difficult to manage because of the large blood loss and must be treated without delay. The use of drug-eluting stents during the last decade allows the treatment of most of these ruptures without the need for surgical intervention.<sup>1,2</sup> In our patient the treatment was extremely rapid, with an excellent final outcome, and no surgical repair of the vessel was needed. The latter would have been a high-risk procedure in this case, because of the extensive coronary artery disease.

## References

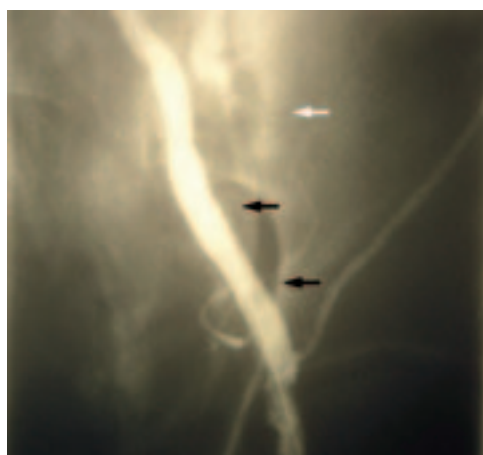
1. Formichi M, Raybaud G, Benichou H, et al: Rupture of the external iliac artery during balloon angioplasty: Endovascular treatment using a covered stent. *J Endovasc Surg* 1998; 5: 37-41.
2. Scheinert D, Ludwig J, Steinkamp HJ, et al: Treatment of catheter-induced iliac artery injuries with self-expanding endografts. *J Endovasc Ther* 2000; 7: 213-220.



**Figure 1.** Arteriography showing the extravasation of a large quantity of contrast medium from the left external iliac artery (arrow).



**Figure 2.** The stent immediately after deployment at the point of vessel rupture (arrows).



**Figure 3.** Final angiographic result, showing complete restoration of the vessel lumen and flow, with no sign of contrast medium extravasation (black arrows). The white arrow shows the region where contrast extravasation occurred previously.